

DEEP LEARNING-BASED BRAIN TUMOR DETECTION

¹Thambala Ramesh, ²Chatragadda Prasanna, ³Jellapuram Roja, ⁴Tokala Mounika

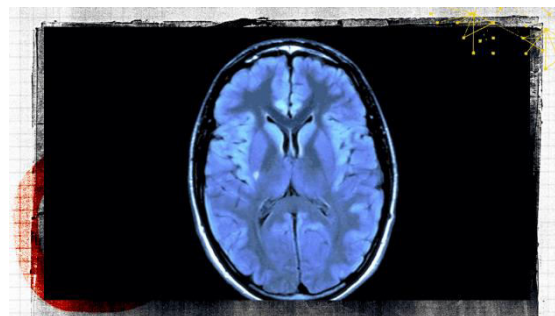
^{1,2,3}Assistant Professor, ⁴Student

Department of CSE Engineering

Abdul Kalam Institute of Technological Sciences, Kothagudem, Telangana

ABSTRACT:

Brain tumour segmentation is an especially difficult but important task in medical imaging. This is due to the possibility of incorrect diagnosis and prognosis resulting from manual categorization. When dealing with large amounts of data, it also takes a lot of labour. Photographically, distinguishing between a brain tumour and normal tissue can be challenging due to their comparable looks and vast range of characteristics. In this study, brain tumours were extracted from two-dimensional MRI images using fuzzy C-Means. Classical classifiers and CNN were then applied. The dataset used in the study contained tumours of different sizes, forms, and intensities. SVM, KNN, MLP, LR, Naive Bayes, Random Forest, and other well-known machine learning algorithms were employed in the standard classifier of the scikit-learn module. Next, convolutional neural networks (CNNs), which are more adept at forecasting results than ordinary neural networks created with Keras or Tensorflow, were studied. CNN's accuracy percentage, according to our study, was 97.87%. This study's main objective is to distinguish between normal and aberrant pixels using statistical and textural data.



I. INTRODUCTION:

There are a variety of non-invasive technologies that may be utilised to investigate the inside of the body using medical imaging. Imaging modalities and procedures used to scan the human body for therapy or diagnosis play a significant part in understanding how to improve people's health, and medical imaging comprises these modalities and methods. In order for additional image processing to be successful, image segmentation is a critical step. Medical picture segmentation seeks to identify tumours or lesions, improve machine vision, and provide a positive outcome for future tests. This has made it difficult to improve the sensitivity and specificity of a tumour or lesion in medical imaging, due to the use of Computer Aided Diagnosis. There is a five-year survival rate of 34% for men and 36% for women for cancer of the nervous system, including the brain, according to the American Cancer Society. The WHO believes that 400,000 people around the world suffer from brain tumours, and that

120,000 people have died as a result in the last few years. Primary brain and other central nervous system tumours (CNS) are expected to increase by 86,970 in the United States this year. Tumors form when abnormal cells proliferate in the brain. Malignant and benign tumours are the two main classifications of tumours. As they grow, malignant brain tumours spread to other parts of the body, putting patients at risk for death. Is capable of affecting both the central nervous system and other brain regions. In order to be classified as primary brain tumours, brain metastasis tumours must have spread from another part of the body. When it comes to cancer, there are two types of brain tumours: malignant and nonmalignant. Consequently, early detection of brain tumours can have a major impact on treatment options and survival rates. There are many MRI pictures created in medical practise, thus manual segmentation of tumours or lesions is a time-consuming and difficult task. MRI, or Magnetic Resonance Imaging, is the most often used method for diagnosing brain tumours and abnormalities. MRI brain tumour segmentation is the most difficult problem in medical image processing since it requires a lot of data. As a result, accurate tumour segmentation in the human brain is a challenge. Using both traditional classifiers and Convolutional Neural Networks, we were able to successfully identify and segment brain tumours without the intervention of humans. This past decade has seen the fast development of more precise and less invasive medical imaging equipment. Researchers can benefit from the expertise of large research institutions in neurobiology and human behaviour. For a medical imaging system

to work, a sensor or energy source must penetrate the human body, as represented in Figure 1. Images are created by combining these signals with mathematically-modified images that are consistent with the energy source. The energy from the human tissue is used to create the photographs, which are then classified based on the amount of energy supplied to the body.

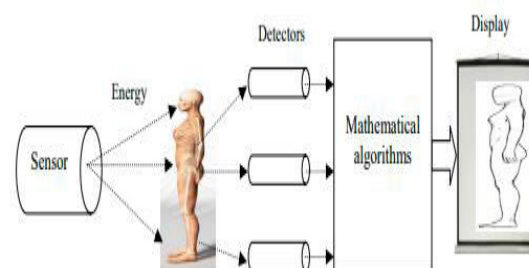


Figure 1. medical imaging system

Signals from these sources are converted into images by applying mathematical manipulation to the data collected by particular detectors that are compatible with the power source. This leads to a classification based on the amount of energy that is delivered to the body, which results in the creation of the images. In order to gain access to the patient's internal organs, a variety of techniques might be employed. These methods work by sending a signal through the body of a patient. The patient's tissues respond to these messages. An image of the patient's internal organs can be produced by detecting the signal that comes from the body. These include X-ray imaging, X-ray Computed Tomography (CT), Magnetic Resonance Imaging (MRI), ultrasound, elastometry and thermography. A total of 5 billion medical imaging examinations were conducted worldwide in the years up to 2010. After the discovery of X-rays in 1895, radiography began. Seeing a picture

of his wife's hand on an X-ray-created photographic plate, Rontgen realised that it could be useful in medicine. On January 1st of that year, Cormack published the first description of CT scanning. At 1972, the first clinical CT scanner was installed in Hounsfield. X-ray CT has revolutionised medical imaging since its introduction and is often regarded as the most significant innovation in radiology since the discovery of X-rays. The first MRI prototypes were tested in 1980 after research on MRI began in the 1970s. Seconds after a brain tumour is discovered, sonography is used as a real-time imaging tool in 1965. In order to detect areas of non-uniform tissue, elastography was developed. For a variety of reasons, elastography — also known as ultrasonic elasticity image, magnetic resonance elastic image, optical elastic image or tactile image—can be used to examine tissues.

For non-invasive brain tumour diagnostics, computer assisted detection is the preferred option. Images are taken using a technique known as magnetic resonance imaging (MRI), which is prone to noise and aberrations during acquisition. In addition to the tumour, other elements in the brain imaging include cerebrospinal fluid, grey matter, white matter, and skull structures.

Unregulated cell proliferation is the primary cause of brain tumours, which have become one of the most lethal diseases in the world to affect human health.

As a result of the diagnosis of a brain tumour, how the medical examination is utilised for surgical and radiation planning is crucial. Many researchers have turned to

magnetic resonance imaging (MRI) for medical image analysis due to its unique imaging processes, including its non-intrusive, non-invasive nature as well as its excellent contrast for soft tissues. Analyzing MRI images for brain tumours is a complex process that requires a thorough understanding of the patient's medical history, as well as a thorough understanding of the tumor's anatomy.

Because of this, accurate and automated segmentation of brain tumours is essential. It's one of the most difficult problems in medical image processing to separate brain tumours from MRI data, due to their unpredictable appearance and shape and the wide range of differences across observers.

II. LITERATURE SURVEY:

Study of Medical Imaging Techniques”

A non-invasive approach of seeing into the body without physically opening it up is Medical Imaging Techniques. To begin with, it was used to aid in the detection and treatment of a wide variety of medical disorders. As with any type of treatment, there are both advantages and disadvantages to medical imaging. Several methodologies are examined in this research. The concepts, advantages, limits, and applications of each are presented. For example, X-ray radiography, PET and Single Photon Emission Computed Tomography (SPECT), thermography, and Terahertz imaging might cause worry. The concepts, advantages, hazards, and implementations of these methods will be explained in great depth. Comparing the image quality (spatial resolution and contrast), safety (effects of ionising radiation on the body, and the heating

effect of radiation on the body), and system availability (real-time information and cost).

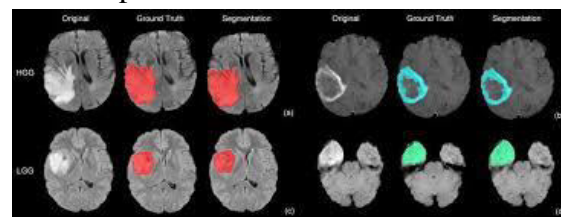
“Image Segmentation for Early Stage Brain Tumour Detection using Mathematical Morphological Reconstruction”

Mathematical Morphological Reconstruction (MMR) can be used to detect brain tumours in their early stages, according to a new study. Images are pre-processed to remove unwanted elements like noise and artefacts before being used for tumour detection. Textural and statistical data collected from the segmented image are used to determine whether the brain tumour depicted in the image is benign or malignant. Splitting an image into smaller chunks results in a very accurate and efficient method of image processing. Brain tumours can be successfully detected in patients using the new method, according to the research.

Brain Tumour Segmentation from Multi-Modality MRI via A Level-Set-Based Model”

The random appearance of tumour tissue in real-world applications makes segmenting a brain tumour with magnetic resonance imaging a difficult and time-consuming task. Level-set based tumour segmentation utilising multimodality magnetic resonance imaging is introduced in this article. We achieve pixel-level tumour segmentation by using three classes: tumour, edoema, and healthy tissue. An aberrant region is first identified using a region-based image processing methodology and then a variational level set formulation is used to estimate the images on both sides of this outline. The

contrast enhancement T1 modality is used in the second stage to distinguish between edoema and tumour tissue in aberrant areas. Our approach is better suited to depicting specific tumour tissue than previous one-modality methods. Testing of the suggested method on both synthetic and clinical brain magnetic resonance imaging shows that it is both effective and simple. In MRI brain images, one of the most challenging and time-consuming jobs is to isolate the tumor's specific region of interest. For this initiative, researchers from all across the world are collaborating on the best-segmenting ROI and imagining a wide range of scenarios. In today's world, neural network segmentation produces impressive results, and its use is expanding at a rapid pace. By combining Mathematical Morphological Operations and the spatial FCM algorithm, Devkota et al. developed an efficient method for segmentation. Following these results, however, the recommended remedy hasn't yet been tested. 86.6 percent of the time, the classifier correctly classifies cancer as 92 percent of the time.



There were 102 images in the collection. Edge detection and adaptive thresholding were both applied to a neural network after the images had been preprocessed using edge detection. The Harris method uses the segmented image to identify distinctive features and convert them to a level number. A healthy brain and one with tumours are detected using one neural network, and the tumour kind is determined using the other. Canny edge

detection was shown to be more accurate when compared to the other model and the findings visualised. To improve texture-based tumour segmentation in longitudinal MRI, Pei et al. advocated using tumour development patterns as unique features. A Learning Vector Quantization model built on the Probabilistic Neural Network paradigm uses label maps to simulate tumour progression and predict cell density after gathering texture (such as fractal and mBm) and intensity characteristics. 18 MRI images were used for testing and the remainder as training for the model, which was then evaluated using a huge number of MRI images. The photos were smoothed using the Gaussian filter. The processing time was lowered by 79 percent using the upgraded PNN approach. Othman et al. created a probabilistic neural network-based segmentation method. Principal Component Analysis (PCA) was used to discover traits and minimise the high dimensionality of the data. PCA. Finally, an evaluation of one's performance is done. There were 20 participants in the training dataset and 15 participants in the testing dataset. The accuracy ranged from 73% to 100% depending on the spread value. As a starting point, they fed all seven training datasets into one Linknet network. With no need for any pre-processing, researchers used an algorithm developed for a CNN to automatically distinguish between the most frequent forms of brain tumours. For a single network, the Dice score is 0.73, while for many networks, the Dice score is 0.79.

III. PROPOSED METHODOLOGY:

For brain tumour segmentation and detection, we suggest two unique models.

Two different models are presented here, one using FCM to segment the tumour, and the other using deep learning to detect tumours. For noisy, clustered datasets, FCM segmentation is superior to other approaches. The process is more time consuming, but the amount of data saved is greater.

Traditional Classifiers: A Proposed Tumor Segmentation and Classification Methodology

A machine learning method was used to segment and identify brain tumours, as well as to compare different classifiers for our model. The seven steps of our proposed Brain picture segmentation system include skull removal, standard classifiers for segmentation, feature extraction, tumour contouring, Fuzzy C Means algorithm segmentation, and morphological procedures. We were able to get positive results thanks to our efforts. Our proposed model is laid forth in the following sections.

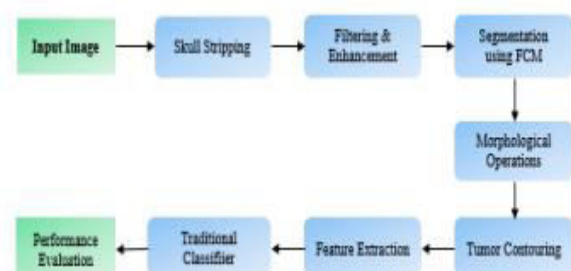

Fig. 1. classification by Traditional Classifiers

This is a critical stage in medical image processing because the backdrop of an MRI picture provides no relevant information and increases processing time. 1) Peeling of skull: We used three steps to remove the skull from the MRI scans during our investigation. The following are the three steps:

This was done in the first phase by using Otsu Threshing to calculate the threshold value and divide the image into front and rear halves, so that the skull could be removed from the image. This method's threshold reduces intra-class variance, which is defined as the weighted sum of deviations from the two classes.

B) Connected component analysis: We used this method to extract the brain only, preserving its structure, rather than dissecting the entire skull.

Pictures need to be enhanced and filtered to reduce noise for better segmentation since brain MRI images are more susceptible to noise than any other medical imaging. By employing Gaussian blur filtering, we improved our segmentation performance by decreasing Gaussian noise.

It was necessary to apply Clustering to help in segmentation. One item of data can be associated with multiple groups using this method. With the fuzzy clustered segmented image, better segmentation was assured.

It is not necessary to remove the skull to do a morphology operation in order to segment the tumour. Morphological approaches were applied in order to accomplish this. An first attempt to separate the MRI image's weakly connected regions was made using erosion. Deterioration will separate our photos into a variety of subcategories. After then, dilation was used.

A thresholding-based intensity-based method was utilised to identify clusters of tumours. Using a dark background, the tumour is highlighted in this image.

For categorization, characteristics were extracted using two categories: The segmented MRI scans were used to extract data such as Mean, Entropy, Centroid, Standard Deviation, and ASM.

We tested our proposed model's ability to identify tumours using K-Nearest Neighbors, Logistic Regression, Multilayer Perceptrons, Naive Bayes, Random Forest, and Support Vector Machine (SVM).

Comparing our proposed segmentation technique with different region-based segmentation algorithms, we found that our model accurately separates the ROI and isolates the tumour component. Figure 5 depicts the entire procedure. Six classification methods were used following segmentation and extraction of tumour features. Overall, SVM performed best with a 92.42 percent success rate. a. The method proposed in this section CNN is a good source for this information.

Convolutional neural networks are commonly employed in medical image processing. Over the years, several scholars have attempted to construct a more precise model for detecting tumours. Using 2D brain MRI data, we aimed to construct an accurate classification model for tumours. The tumour may be detected by a fully connected neural network, however we used CNN because of parameter sharing and connection sparsity.

For the detection of tumours, a five-layer convolutional neural network is introduced and implemented. Using a seven-phase model that incorporates the hidden layers, we are able to detect tumours with the greatest clarity. The proposed approach and a brief storey are below.

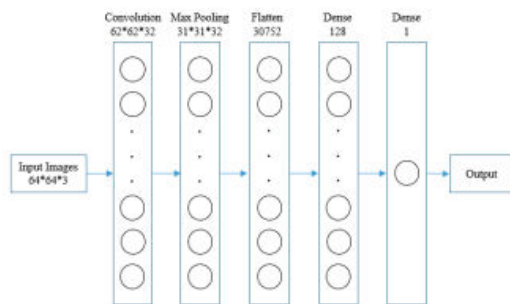


Fig. 2. Proposed Methodology for tumour detection using 5-Layer CNN

A 64x64x3 matrix To construct the input shape of the MRI pictures, the convolutional layer is used as the initial layer, transforming each image to be homogeneous. After gathering all of the images in the same aspect, we used 32 convolutional filters of size 3*3 each with the support of three channel tensors to create a convolutional kernel. The activation function ReLU is utilised to ensure that the output does not conflict with it in any way. It is possible to reduce the number of parameters and compute time in this ConvNet architecture by reducing its spatial scale. The Max Pooling layer is suitable for working on a brain MRI image, which can be contaminated by overfitting. Models of geographical data that are consistent with our input image are created using MaxPooling2D. This convolutional layer is 31*31*32 pixels in size. All photographs are divided in both spatial dimensions, therefore there is a tuple of two numbers that must vertically and horizontally scaled down. It is only after the application of the pooling layer that a feature map is formed. We need to flatten the entire matrix of input photographs into a single column vector after the pooling procedure is complete. Neural Networks can be used to analyse data that is fed into them. Two fully

interconnected layers were used. The dense layer was represented by Dense-1 and Dense-2. Dense functions are used in Keras to process neural networks, and the resulting vector is fed into the neural network's first layer as an input. The hidden layer contains 128 nodes. When we had to reduce the number of dimensions or nodes in our model, we did so because they were directly related to the quantity of computational resources we needed. Due of ReLU's strong convergence performance, the activation function is used. The model employed the second fully connected layer as its final layer after the first dense layer. We used a sigmoid function with a single node as an activation function in this layer to save time and resources. Despite the fact that scaling the sigmoid activation function may hamper deep learning, the number of nodes is greatly reduced. It is shown in Figure 3 how the proposed CNN model works.

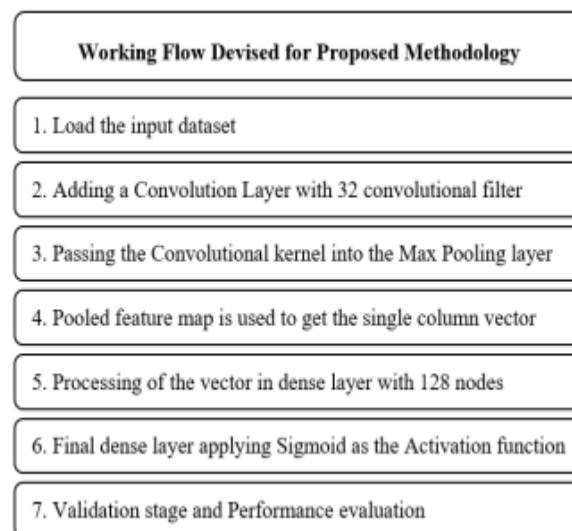


Fig. 3. Working flow of the proposed CNN Model.

To gauge the model's accuracy in recognising tumours, we used the Adam optimizer and binary cross-entropy as a

loss function. In order to assess the model's performance, we used the method depicted in Fig. 4.

```

Algorithm 1: Evaluation process of CNN model
1 loadImage();
2 dataAugmentation();
3 splitData();
4 loadModel();
5 for each epoch in epochNumber do
6   for each batch in batchSize do
7      $\hat{y} = \text{model}(\text{features});$ 
8     loss = crossEntropy(y,  $\hat{y}$ );
9     optimization(loss);
10    accuracy();
11    bestAccuracy = max(bestAccuracy, accuracy);
12 return
    
```

Fig. 4. Algorithm of the performance evaluation

Table-I contains all of the hyper-parameter values. The accuracy rate is approximately 97.87 percent.

TABLE I. HYPERPARAMETER VALUE OF CNN MODEL

Stage	Hyper-parameter	Value
Initialization	bias	Zeros
	Weights	glorot uniform
Training	Learning rate	0.001
	beta_1	0.9
	beta_2	0.999
	epsilon	None
	decay	0.0
	amsgrad	False
	epoch	10

Stage	Hyper-parameter	Value
	Batch_size	32
	steps_per_epoch	80

IV. EXPERIMENTAL RESULTS:

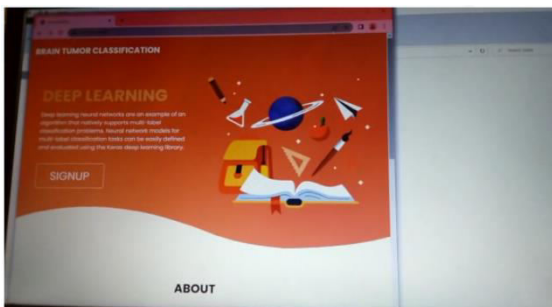


Fig.5 Main screen

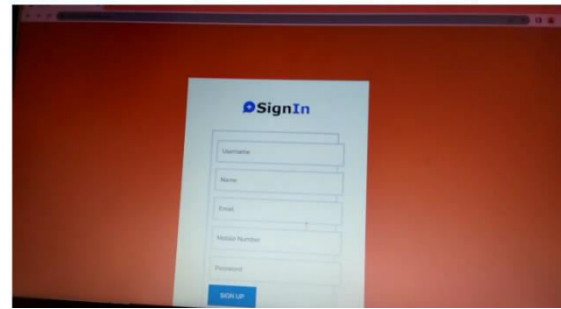


Fig.6: Signup

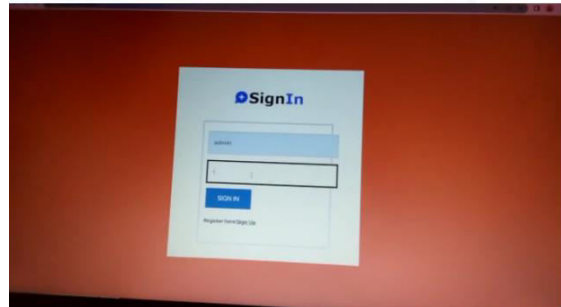


Fig.7: Login

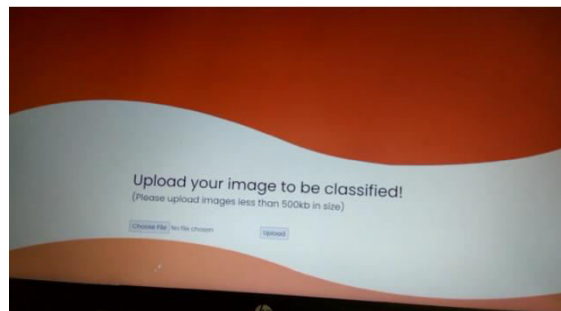


Fig.8: Upload image

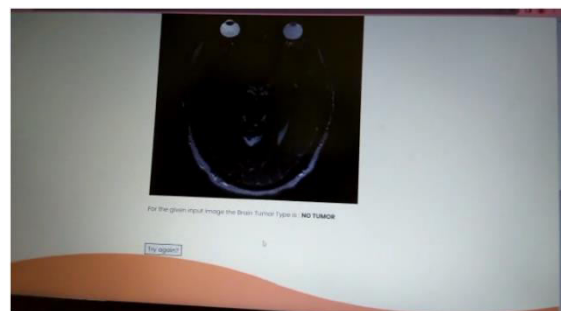


Fig.9: Predicted result

V. CONCLUSION:

Medical image processing relies heavily on image segmentation because of the sheer size of the images. We used MRI and CT scan images to separate brain

tumours. Use of MRI for the segmentation and classification of brain tumours is the most common use. For tumour segmentation, we employed Fuzzy C-Means clustering, which effectively predicts tumour cells. After segmentation, classical classifiers and Convolutional Neural Networks were used to classify the data. Traditional classifiers such as K-Nearest Neighbor, Support Vector Machi, and others were utilised and compared in this section. SVM was the most accurate of these proven approaches. In addition, we used a Computer Neural Network (CNN). Our goal is to produce a dataset that simplifies the process of working with a huge number of data points.

REFERENCES:

- [1] Kasban, Hany & El-bendary, Mohsen &Salama, Dina. (2015). "A Comparative Study of Medical Imaging Techniques". *International Journal of Information Science and Intelligent Systems*. 4. 37-58.J. Clerk Maxwell, A Treatise on Electricity and Magnetism, 3rd ed., vol. 2. Oxford: Clarendon, 1892, pp.68–73.
- [2] D. Surya Prabha and J. Satheesh Kumar, "Performance Evaluation of Image Segmentation using Objective Methods", *Indian Journal of Science and Technology*, Vol 9(8), February 2016.
- [3] Brain Tumour: Statistics, Cancer.Net Editorial Board, 11/2017 (Accessed on 17th January 2019)
- [4] KavithaAngamuthuRajasekaran and ChellamuthuChinnaGounder, *Advanced Brain Tumour Segmentation from MRI Images*, 2018.
- [5] General Information About Adult Brain Tumours". NCI. 14 April 2014. Archived from the original on 5 July 2014. Retrieved 8 June 2014. (Accessed on 11th January 2019)
- [6] M. Young, *The Technical Writer's Handbook*. Mill Valley, CA: University Science, 1989.
- [7] B. Devkota, AbeerAlsadoon, P.W.C. Prasad, A. K. Singh, A. Elchemi, "Image Segmentation for Early Stage Brain Tumour Detection using Mathematical Morphological Reconstruction," 6th International Conference on Smart Computing and Communications, ICSCC 2017, 7-8 December 2017, Kurukshetra, India.
- [8] Song, Yantao& Ji, Zexuan& Sun, Quansen&Yuhui, Zheng. (2016). "A Novel Brain Tumour Segmentation from Multi-Modality MRI via A Level-Set-Based Model". *Journal of Signal Processing Systems*. 87. 10.1007/s11265-016-1188-4.
- [9] Ehab F. Badran, EsraaGalal Mahmoud, NadderHamdy, "An Algorithm for Detecting Brain Tumours in MRI Images", 7th International Conference on Cloud Computing, Data Science & Engineering - Confluence, 2017.
- [10] Pei L, Reza SMS, Li W, Davatzikos C, Iftexharuddin KM. "Improved brain tumour segmentation by utilising tumour growth model in longitudinal brain MRI". *Proc SPIE IntSoc Opt Eng*. 2017.